HISTOLOGICAL OBSERVATION OF DAMAGE TO DERMAL TISSUE OF FUR SEAL CAUSED BY NET ENTANGLEMENT

Masayuki Nakajima
Izu-Mito Sea Paradise
3-1 Nagahama, Uchiura
Numazu, Shizuoka, 410-02 Japan

Hiromoto Yasuda
Faculty of Medicine, Teikyo University
2-11-1, Kaga, Itabasi-ku
Tokyo, 173 Japan

and

Kazumoto Yoshida
National Research Institute of Far Seas Fisheries
Fisheries Agency, the Government of Japan
Shimizu, Shizuoka, 424 Japan

ABSTRACT

In 1984 and 1985, experimental studies on the damage to northern fur seals by net entanglement were carried out in Izu-Mito Sea Paradise, an aquarium where fur seals are kept for the National Research Institute of Far Seas Fisheries, Fisheries Agency, the Government of Japan (formerly the Far Seas Fisheries Research Laboratory, Fisheries Agency of Japan).

Two adult female fur seals, captured off Sanriku, northern Japan, in March 1980, were experimentally entangled in fishing net fragments in late January 1984. One seal, No. 1-7, 123 cm in body length and 39.5 kg in body weight, and an estimated 10 years of age, was entangled around the neck with a net fragment weighing 200 g. The second seal, No. 1-8, 113 cm in body length and 36.0 kg in body weight, with an estimated age of 10 years, was entangled with net fragments 300 g in weight. Both seals were kept in the same environment.

Seal No. 1-8 died in September 1984 after 226 days of entanglement, having suffered traumatic damage to pelage and skin. Net fragments were removed from No. 1-7 in March 1985. Damage to skin and pelage was not observed even after 14 months on entanglement, although the state of entanglement was similar to No. 1-8. She died in February 1986. Abnormality was not observed in the skin at the time of death. Cause of death was acute pneumonia in both cases. When they were alive, No. 1-7 was in good health and No. 1-8 was slightly unwell.

In R. S. Shomura and M. L. Godfrey (editors), Proceedings of the Second International Conference on Marine Debris, 2-7 April 1989, Honolulu, Hawaii. U.S. Dep. Commer., NOAA Tech. Memo. NMFS, NOAA-TM-NMFS-SWFSC-154. 1990.

INTRODUCTION

Fur seal are known to have died from entanglement in fishing net fragments and packing bands (Scordino 1985). It was pointed out that net entanglement may constitute one of the major factors for the decrease in the Pribilof Islands populations of the northern fur seal, *Callorhinus ursinus*. In order to understand the actual state and effects of entanglement, the National Research Institute of Far Seas Fisheries, Fisheries Agency, the Government of Japan (formerly the Far Seas Fisheries Research Laboratory, Fisheries Agency of Japan) conducted field surveys of fur seals and marine debris on breeding islands and at sea. Also, experimental studies were carried out concerning the process of entangling and the effects of entanglement on the behavior of fur seals, both of which were difficult to observe in a natural environment. Little has yet been reported about traumatic wounds to the skin of fur seals caused by net entanglement. In this study, macroscopic observation was conducted on damage inflicted by net entanglement to the pelage and skin of fur seals kept in captivity. Post-mortem histological examination was also made of the lesions of the dermal tissues.

MATERIALS AND METHODS

The experiment was conducted for about 14 months from 10 January 1984 to 31 March 1985 in a breeding facility of the Izu-Mito Sea Paradise, an aquarium in Numazu, central Japan. Two female northern fur seals, with identification numbers 1-7 and 1-8 and an estimated age of 10 years, were used. These individuals were entangled with net fragments during an experiment on the mechanism of entanglement. Seal No. 1-7 was entangled in trawl net fragments of 200 g on 20 January 1984, and No. 1-8 was entangled in a trawl net fragment weighing 100 g on 28 January 1984 and in another fragment of 200 g on 29 January 1984. Nets were removed from No. 1-7 at the end of the experiment on 31 March 1985. Behavior of the two seals and damage to pelage were observed every day in the morning and evening. The net fragments used in the experiment were commercial trawl nets made of polyethylene, with a twine size of 3.4 mm and a mesh size of 24 cm. The nets were cut into 100- and 200-g pieces.

The two individuals were kept in an open breeding facility (Fig. 1) from 10 January to 10 March 1984; afterward they were brought to an indoor breeding pool 1.6 m wide, 2.4 m long, and 1.0 m deep. No landing place was provided in the pool, in order to prevent resting on land except for the breeding season, in imitation of pelagic life. The experimental animals were fed with defrosted mackerel each day at 1000 and 1630. Average daily food consumption of No. 1-7 was 3.8 kg/day (0-5.5 kg/day) and that of No. 1-8 was 2.8 kg/day (0.4-4.0 kg/day). Body weight of No. 1-7 remained almost constant during the entire experiment period, while that of No. 1-8 declined near the time of death.

Necropsy was conducted immediately after the death of the entangled animals for macroscopic and histological inspection of the skin lesions. Histological samples of dermal tissue were fixed with 20% formaldehyde, embedded in paraffin, and cut into sections 4 microns thick with a sliding

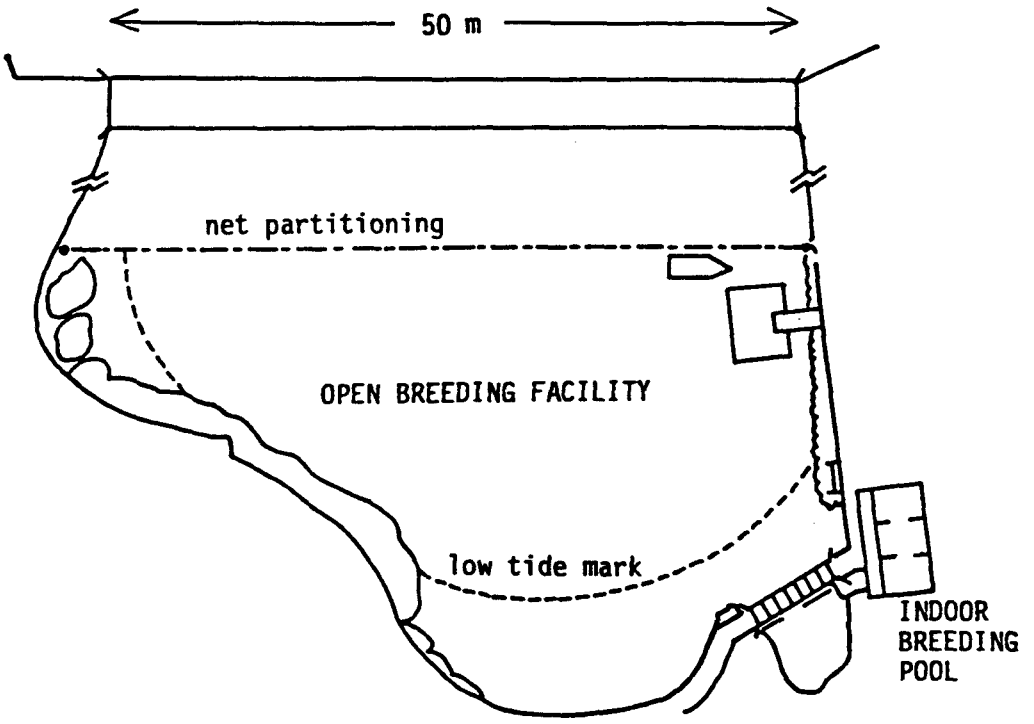

Figure 1.--The breeding facilities at Izu-Mito Sea Paradise.

microtome. The sections were dyed using hematoxylin eosin staining or Masson's method.

Atmospheric temperature during the period ranged from -5° to 30.1°C, water temperature ranged from 12.0° to 28.3°C, and relative humidity ranged from 33 to 92%. Details of the fur seals used in the experiment are given in Table 1.

RESULTS

Behavior of No. 1-7 and Description of Net Entanglement

This individual was in quite good health. On 20 January 1984, she was entangled around the neck by a bundle of net made into a collar. There was a space between the net collar and the neck into which one finger could be inserted. No damage to the entangled part was observed even after 14 months. Net fragments were removed at the end of the experiment on 31 March 1984. The individual remained in good health with a good appetite, finally dying on 25 February 1986, 11 months after the removal of the nets. Port-mortem examination revealed small whitish nodules about 5 mm in size scattered throughout the lungs. No pus was found in the nodules. The cause of death was diagnosed as acute pneumonia. The cervical region where the net had been entangled was also inspected, but no anomaly was recognized.

Table 1.--Details of the two female northern fur seals used in this study.

Chronology of the experiment	Seal No. 1-7	Seal No. 1-8
Capture		
Date	4 March 1980	7 March 1980
Location	Lat. 36°40'N long. 141°27'E	Lat. 36°30'N long. 141°15'E
Transport to aquarium		
Date	8 March 1980	8 March 1980
Body weight (kg)	29.0	30.5
Beginning of experiment		
Date	10 January 1984	10 January 1984
Estimated age	10	10
Body length (cm)	123	113
Body weight (kg)	39.5	36.0
Net entanglement		
Starting date	20 January 1984	28 January 1984
Weight of nets (g)	200	100
		29 January 1984
		200
Date of removal	31 March 1985[a]	10 September 1984[b]
Death		
Date	25 February 1986	10 September 1984
Body length (cm)	120.5	114.5
Body weight (kg)	34.5	30.5
Cause of death	Acute pneumonia	Acute pneumonia

[a]Experiment ended.
[b]Seal died.

Behavior of No. 1-8 and Description of Net Entanglement

Judging from daily behavior and feeding activities, this individual was considered in somewhat poor health even before it was entangled in nets. Two net fragments were placed around its neck on 28 and 29 January 1984.

The entangled nets made up a collar consisting of 17 meshes in a bundle (Figs. 2 and 3). The collar was 14 cm in inner diameters, 44 cm in inner circumference, 100 cm in outer circumference, and 7 to 9 cm thick. No remarkable change in behavior was observed after net entanglement. On the morning of 6 June 1984, she delivered a female pup, 65 cm long and 4.2 kg in weight, but the pup was dead when it was discovered. Anatomical inspection revealed the cause of the pup's death to be drowning. Seal No.

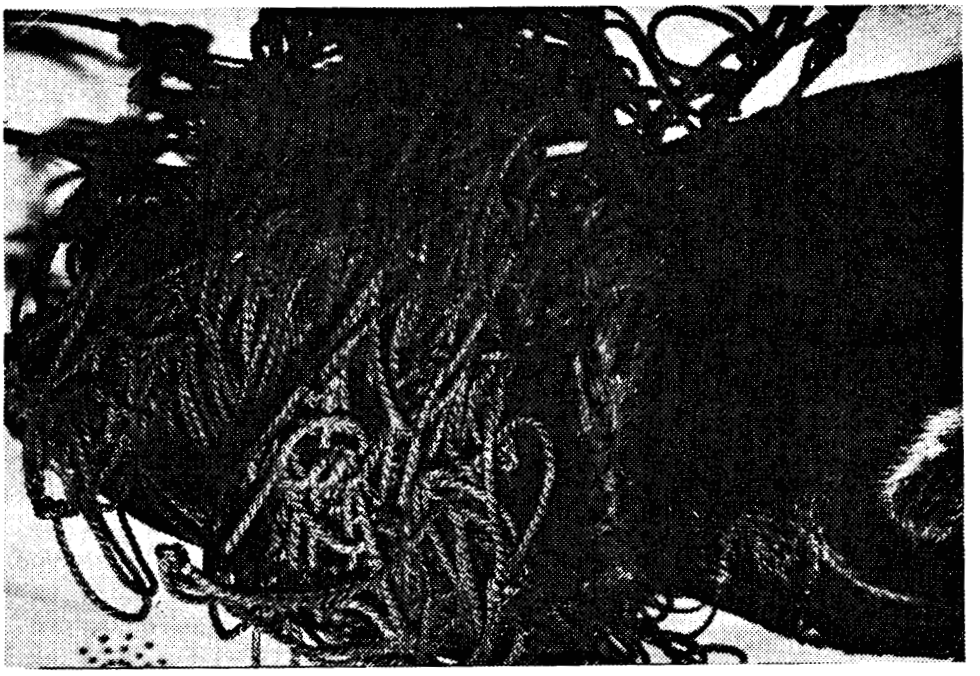

Figure 2.--State of entanglement of fur seal No. 1-8.



Figure 3.--Collar of entangled net on fur seal No. 1-8.

1-8 ate poorly from 4 September 1984 and died on 10 September, 226 days (7.5 months) after the initiation of net entanglement. Macroscopic and histological observations of the entangled part are described below.

Diagnosis of the Lesions on No. 1-8

The nutritive condition of the body as a whole was moderate. No external scars were observed except around the neck. In macroscopic observation, hair was worn or lost all around the neck, and the epidermis was exposed in some parts. Several wounds due to abrasion by the attached nets were conspicuous: one large scar 1-3 cm wide and 5 cm long on the right side of the neck and two other wounds of 1-2 cm at the scruff. Cross sections of the lesions revealed hardened hyperdermis and a thin muscle layer. The thick adipose tissue consisted of yellow and white parts (Figs. 4 and 5).

In the histological examination, sections of the injured dermal tissue showed degeneration and loss of hair follicles and hair matrices, and degeneration of the hair itself. Connective tissues were partially worn out and necrotized. Proliferation of collagen fiber was observed in the peripheral connective tissues. In these parts, degenerated inner membranes, supposedly derived from venous sinus, were also observed. Rupture and degeneration of muscle layers were distinctive and a part of the connective tissues had been replaced. Congestion and edema of venous ducts were conspicuous and their inner membrane revealed degeneration. However, cell infiltration and inflammatory reactions were indistinctive (Figs. 6 and 7).

As for visceral organs, hyperemia was observed in the lungs and accumulation of blood was conspicuous in the heart. Other visceral organs showed no remarkable change. The cause of death was presumed to be acute pneumonia.

DISCUSSION

No injury occurred around the neck of No. 1-7, entangled in 200 g of fishing nets for 14 months. Seal No. 1-8, entangled at the neck in 300 g of nets for 7.5 months, suffered abrasion of hair and skin. These differences seemed to have been caused by such factors as physical condition, and the amount and tightness of the entangled nets. After anatomical inspection, the cause of death for both individuals was diagnosed as acute pneumonia. As a future task, it will be necessary to examine bacterial infections from the wounds caused by entanglement.

As fur seals used in this experiment were adult, no increase in body weight was observed during the experiment period of 7.5 to 14 months. But it can be assumed that when a young, growing animal becomes entangled in fishing nets, even if the net fragment is small and loose at first, it will gradually become tighter as the animal grows, causing serious damage and possibly death.

Figure 4.--Abraded wound in the pelage and skin of No. 1-8.

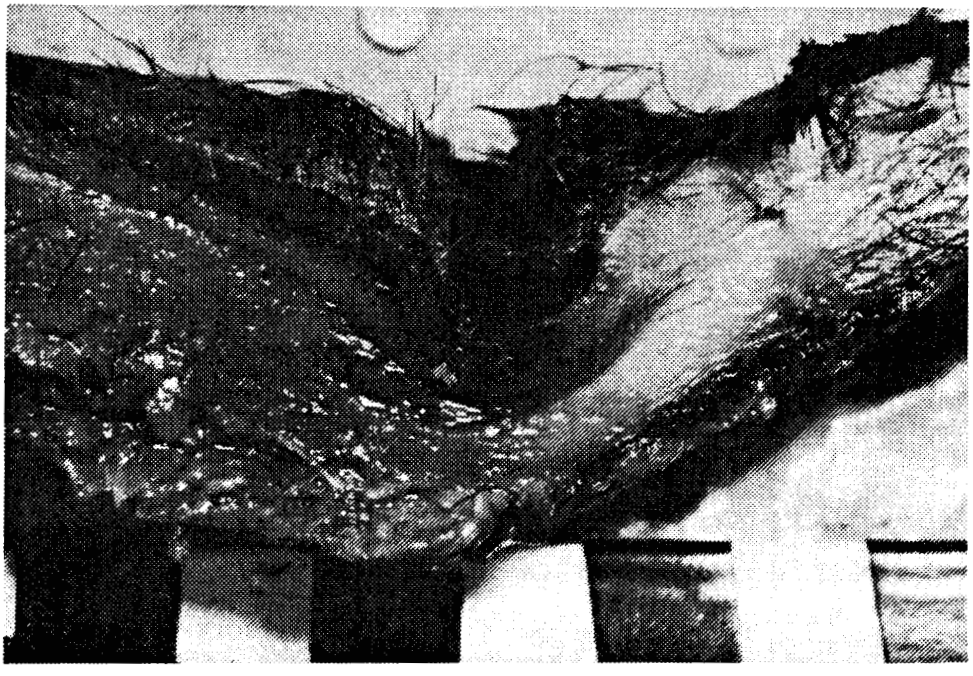

Figure 5.--Cross section of dermal tissues through the lesion on the neck of No. 1-8.

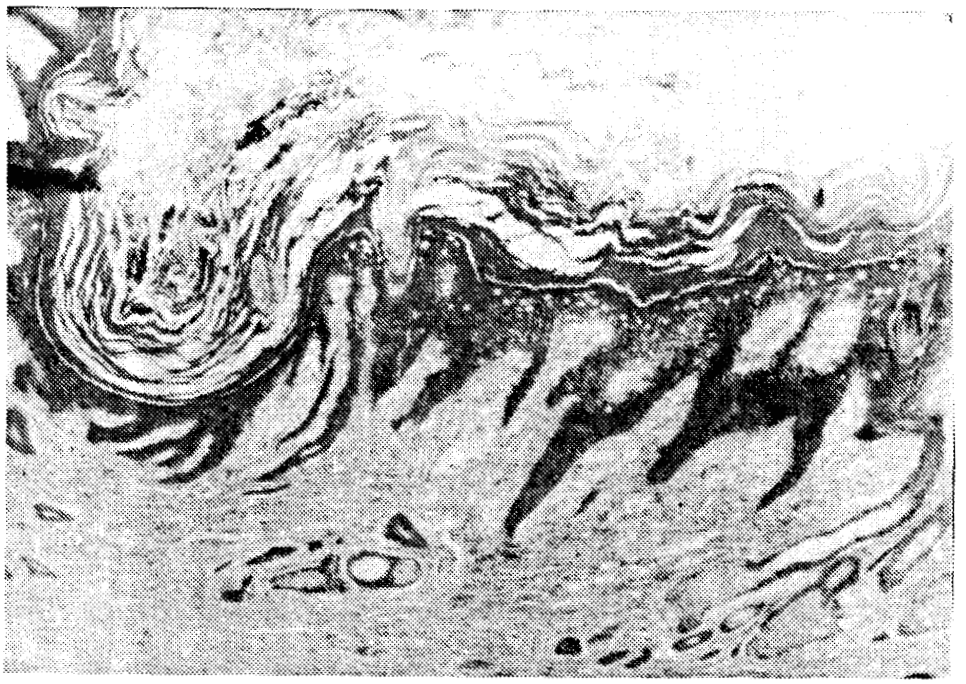

Figure 6.--Section through a lesion in the cervical region of No. 1-8 (hematoxylin eosin staining × 40).

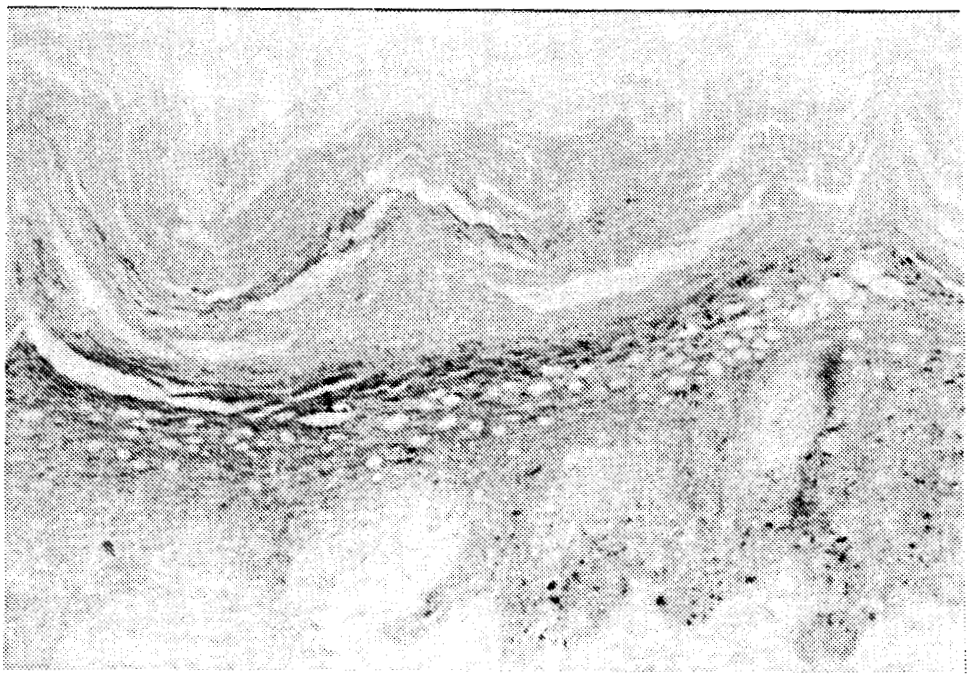

Figure 7.--Section through a lesion in the cervical region of No. 1-8 (Masson's staining × 100).

ACKNOWLEDGMENTS

Deep appreciation is expressed to all who cooperated in the research, especially to N. Baba and M. Kiyota of the National Research Institute of the Far Seas Fisheries, the staff of the Clinical Inspection Center of Numazu Ishikai Hospital, and breeding technicians of Izu-Mito Sea Paradise. Thanks are also due to the Fishing Ground Preservation Division, the Fisheries Agency of the Government of Japan.

REFERENCES

Scordino, J.
1985. Studies on fur seal entanglement, 1981-84, St. Paul Island, Alaska. *In* R. S. Shomura and H. O. Yoshida (editors), Proceedings of the Workshop on the Fate and Impact of Marine Debris, 26-29 November 1984, Honolulu, Hawaii, p. 278-290. U.S. Dep. Commer., NOAA Tech. Memo. NMFS, NOAA-TM-NMFS-SWFC-54.